

History of Carotid Stroke

Alex B. Munster, BSc; Ankur Thapar, MRCS, PhD; Alun H. Davies, DM, DSc

Classical Antiquity

[The] two branches which they call carotides or soporales, the sleepy arteries, because they being obstructed, or any way stopt we presently fall asleep.

—Ambroise Paré (ca. AD 1510–1590)¹

Current understanding of carotid artery disease begins in Ancient Greece. The term carotid is derived from the Ancient Greek *karos* (κάρως), meaning to stupefy. This first description is ascribed to Hippocrates (ca. 460–370 BC) but defined in the later accounts of Rufus of Ephesus (fl. ca. AD 100), who stated that the term was used because superficial compression of the vessels was known to induce stupefaction.

The importance of the carotid arteries was even evident in the timeless art of the era. The 31st metope (a rectangular architectural element) from the south side of the Parthenon in Athens (Figure 1) depicts a centaur gripping the neck and compressing the left carotid artery of a Lapith (member of a mythological Thessalian people) during the legendary Centauromachy battle. Galen (ca. AD 131–201) attributed the loss of consciousness to compression not of the carotid arteries but of “sensitive nerves” located proximal to the vessels.² Today cardiologists recognize a similar syndrome of carotid sinus syncope, tested for through carotid baroreceptor hypersensitivity.

The most devastating consequence of carotid artery disease is stroke, which was referred to during classical antiquity as apoplexy. Hippocrates and Galen were both aware that the hemiplegia often accompanying apoplexy resulted from a lesion in the contralateral cerebral hemisphere. Indeed, Hippocrates proposed that “unaccustomed attacks of numbness and anesthesia” (the first description of transient ischemic attacks) precede and may predict oncoming apoplexy.³

The Age of Rationalism

European progress in the understanding of stroke remained stagnant until after the Middle Ages. The first suggestion of a link between symptoms of cerebral arterial insufficiency and carotid pathology was made during the 17th century by the Swiss pathologist Wepfer (AD 1620–1695). He postulated that interruption of blood supply to the brain was the

cause of apoplexy. In his *Historiae Apoplecticorum* (1658), he described 4 cases of apoplexy that at autopsy were found to have occlusive thrombus in the carotid artery. It was unclear at this time whether the thrombus found in the carotid arteries represented embolization from the heart or in situ thrombosis because the significance of atherosclerosis had not yet been established.

Wepfer’s influence would, however, be superseded by the work of his contemporary Willis (AD 1621–1675). *Cerebri Anatome*, published by Willis 6 years after the text of Wepfer, made an attempt to link function with structure. It was in this work that Willis coined the term neurology and described the *circulus arteriosus cerebri* that now bears his name. Despite Wepfer and others (Fallopian, Casseri, Vesling and Ridley) also describing the circulatory anastomosis, it was Willis who realized its true significance. The clinical importance of the cerebral arterial circle was confirmed when Willis autopsied a man who died of a mesenteric tumor, who in life was neurologically asymptomatic:

When his skull was opened we noted amongst the usual intracranial findings, the right carotid artery, in its intracranial part, bony or even hard, its lumen being almost totally occluded; so that the influx of the blood being denied by this route, it seemed remarkable that this person had not died previously of an apoplexy.

—Thomas Willis (AD 1621–1675)⁴

In the following century, research by Petit (AD 1674–1750) corroborated the notion held by Willis and further averted the attention of medical science from an extracranial cause for apoplexy. In his posthumous paper of 1765, Petit reports the autopsy of a patient who had an aneurysm of the right common carotid artery bifurcation, which spontaneously resolved 7 years before the patient’s death. The autopsy revealed thrombotic occlusion of the right carotid artery, reaffirming Willis’s idea that the brain could survive when supplied by only one carotid artery.⁵ In fact, in the 1900s, unilateral carotid ligation was practiced as a treatment for intracranial internal carotid aneurysm.⁶

van Swieten (AD 1700–1772), in his 1754 commentaries on Boerhaave (AD 1668–1738), discussed the embolic hypothesis,

Received November 15, 2015; final revision received December 11, 2015; accepted December 11, 2015.

From the Faculty of Biology, University of Cambridge, Cambridge, UK (A.B.M.); London Postgraduate School of Surgery, London, UK (A.T.); and Academic Section of Vascular Surgery, Imperial College London, 4 East, Charing Cross Hospital, London, UK (A.H.D.).

Correspondence to Alun H. Davies, FRCS, MA, DM, DSc, FHEA, FEBVS, FACPh, Academic Section of Vascular Surgery, Imperial College London, 4 East, Charing Cross Hospital, London, UK W6 8RF. E-mail a.h.davies@imperial.ac.uk

(*Stroke*. 2016;47:e66–e69. DOI: 10.1161/STROKEAHA.115.012044.)

© 2016 American Heart Association, Inc.

Stroke is available at <http://stroke.ahajournals.org>

DOI: 10.1161/STROKEAHA.115.012044

giving the example of bloodstream debris arising from the heart and its great vessels being carried to, and impeding the flow of, distal blood vessels. In spite of the fact that van Swieten reported no cases of carotid apoplexy, he postulated that should such a process occur to the major cerebral arteries, there could be a devastating loss of brain function. This was the first suggestion that apoplexy could be caused by a cerebral embolism.

The 19th Century

One-hundred years later, Abercrombie (AD 1780–1844) considered the causes of apoplexy in his discussions on “inflammation of the substance of the hemispheres” (encephalitis). He made reference to several cases which passed with varying rates into cerebral “ramollissement” (French for softening), a term introduced by Rochoux 20 years earlier. Abercrombie provided an alternative cause for ramollissement: circulatory failure. He presented the case of a gentleman who suffered a total of 7 apoplectic attacks, the last of which ultimately proved fatal. On performing autopsy, he wrote:

There was extensive disease in the arteries of the brain, their coats being thickened, and in many places ossified. This was very remarkable in the principal trunks of the carotids and vertebrals, ... The internal carotids seemed considerably larger than usual, and their coats were much thickened; ... There seems every reason to believe that such cases often depend upon disease of the arteries of a portion of the brain.

—John Abercrombie (AD 1780–1844)⁷

Abercrombie thus advanced the notion that ramollissement (infarction) could occur secondary to cerebrovascular disease. Carswell (AD 1793–1857) was the first to prove that ramollissement was a necrotic process driven by cerebroarterial obliteration. In *Pathological Anatomy: illustrations of the*

elementary forms of disease (1838), Carswell detailed autopsy findings in subjects with ramollissement:

... if the obliteration has taken place in the carotid or one of its principal divisions within the cranium, the greater part or the whole of a hemisphere may be softened. ... When effusion takes place, it is probably the consequence of rupture of the obliterated vessels, or of some of the smaller ones having remained pervious and yielding to the increased momentum of the blood.

—Robert Carswell (AD 1793–1857)⁸

Carswell turned attention back to the carotid as a cause for cerebral injury, but why some died from this and others remained asymptomatic as Willis had demonstrated was unclear.

After Carswell, in 1855, Gull (AD 1816–1890) wrote of a patient with occlusion of the innominate and left carotid arteries, noting an association between this pathology and with what is now known to be archetypal stroke symptomatology.⁹ The following year, Virchow (AD 1821–1902), the father of modern pathology, published his great work *Gesammelte Abhandlungen zur wissenschaftlichen Medicin* (Collected Essays on Scientific Medicine), wherein he coined the terms thrombosis, ischemia, and embolus, as well as revived the expression arteriosclerosis. It was in this volume that Virchow described, at autopsy, a case of in situ thrombosis within the carotid artery, associated with ipsilateral monocular blindness in the presence of patent central retinal and ophthalmic arteries.

In the same year, Savory (AD 1826–1895) commented on the case of a young woman having vertigo, left-sided visual difficulty, and right-sided weakness of the limbs. The autopsy revealed obliteration of the left carotid and both subclavian arteries, together with disorganization of the surface of the left cerebral hemisphere “to the depth of an inch or more”.¹⁰ Observations from one of Virchow’s doctoral students, Kussmaul (AD 1822–1902), demonstrated monocular blindness with occlusive




Figure 1. The 31st metope from the south side of the Parthenon in Athens. On display in the British Museum, the southern aspect metopes depict the battle between the centaurs (left) and the Lapiths (right) at the wedding of Peirithus, the king of the Lapiths. The left carotid artery of the Lapith is here being intentionally compressed to induce unconsciousness. Photograph courtesy of Colin Howley. Used with permission.

thrombus in the ipsilateral carotid artery.¹¹ Later, in 1881, Franz Penzoldt (AD 1849–1927) published the case of a patient who exhibited sudden-onset blindness of the right eye with delayed contralateral hemiplegia. The autopsy revealed significant softening of the right cerebral hemisphere and a thrombotically obstructed right common carotid artery.¹²

The 20th Century

By the turn of the century, the link between carotid occlusion and cerebral infarction was emerging. Chiari (AD 1851–1916) developed the thromboembolic hypothesis with work on ulcerated plaque and surface thrombus. His findings were the first to show that an atherosclerotic carotid bifurcation was a prominent source of stroke-inducing cerebral emboli and led him to propose that the carotid arteries should be examined at autopsy as a potential cause of stroke. In 1914, Ramsay Hunt (AD 1872/74–1937) identified that both occlusion and stenosis of the carotid could induce cerebral syndromes and coined the term cerebral intermittent claudication to describe this.

The sixth decade saw the advent of the genius of Miller Fisher (AD 1913–2012), who, in 1951¹³ and 1954,¹⁴ at last made the link between carotid bifurcation disease and stroke (Figure 2). Using the new technique of cerebral angiography developed by Moniz, Fisher definitively outlined the clinical picture of atherosclerotic carotid lesions, noted the varying degrees of stenosis that could subsequently manifest, and identified several resultant cerebral syndromes. He, like Chiari before, detailed in many stroke cases the absence of other embolic sources, leaving the carotid bifurcation as the culprit lesion. Fisher’s landmark articles brought major attention to the carotid arteries as pathological substrates for stroke, bringing forth probably the most prophetic statement to have ever been made in the field:

It is even conceivable that some day vascular surgery will find a way to by-pass the occluded portion of the artery during the period of ominous fleeting symptoms. Anastomosis of the external carotid artery or one of its branches with the internal carotid artery above the area of narrowing should be feasible.

—C. Miller Fisher (AD 1913–2012)¹³

It was not long until his prophetic words were acted upon. The first attempt to surgically remedy a carotid stenosis is credited to DeBakey, who performed the first successful thromboendarterectomy on August 7, 1953. Other contemporaries were Carrea et al in 1951 and later Eastcott et al in 1954; however, in both these cases, the procedures were end-to-end reconstructions of the carotid bifurcation rather than endarterectomy. Eastcott, a former surgeon at the authors’ institution, differentiated the cause of crescendo transient ischemic attacks between flow limitation and thromboembolism by injecting the patient with intravenous histamine, lowering their blood pressure, but without reproducing symptoms. Resection of a stenotic carotid bifurcation and end-to-end anastomosis abolished the patient’s repeated attacks. Since this time, numerous trials have demonstrated the efficacy of carotid endarterectomy in the prevention of fatal and disabling stroke from carotid thromboembolism.

In 1980 Kerber took the step of performing retrograde common carotid angioplasty during a surgical endarterectomy for tandem lesions. He commented prophetically:

The brain is an unforgiving organ, and angiographers are reluctant to attack carotid or vertebral artery stenoses.

—Charles W. Kerber¹⁵

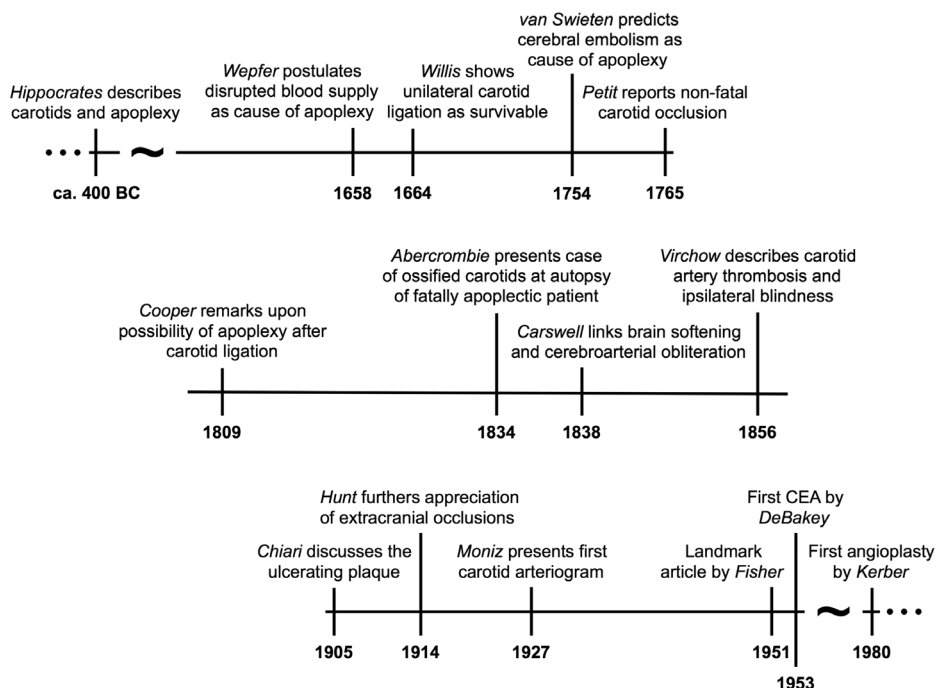


Figure 2. Landmark historical advances in the understanding of carotid stroke.

Conclusions

Since the pathological substrate of carotid disease is atherosclerosis, the fundamental approach to therapy must be directed at the prevention or cure of that disorder.

—C. Miller Fisher (AD 1913–2012)¹⁴

The story of carotid stroke is not over. Today's challenges include identifying which plaques are prone to rupture, whether endovascular treatment will supersede surgical endarterectomy, and whether improvements in medical therapy can reduce the unnecessary number of interventions currently performed.

Acknowledgments

The aim of this review was to provide a succinct historical timeline of carotid-origin stroke. The authors offer apology for any persons who we have not been able to include because of a limited word count. A.B. Munster participated in drafting and revising the article for intellectual content, as well as designing and coordinating the review. A. Thapar participated in revising the article for intellectual content, as well as conceptualizing and supervising the review. A.H. Davies participated in revising the article for intellectual content, as well as conceptualizing, supervising, and coordinating the review.

Disclosures

None.

References

1. Paré A. *The Workes of That Famous Chirurgion Ambrose Parey. Translated out of Latine and compared with the French*, by T. Johnson. London: Cotes & Du-gard; 1649.

2. Crile GW. *An Experimental and Clinical Research into Certain Problems Relating to Surgical Operations*. Philadelphia, PA: J. B. Lippincott Co; 1901:164.
3. Robicsek F, Roush TS, Cook JW, Reames MK. From Hippocrates to Palmaz-Schatz, the history of carotid surgery. *Eur J Vasc Endovasc Surg*. 2004;27:389–397. doi: 10.1016/j.ejvs.2004.01.004.
4. Willis T. *Cerebri Anatome: cui Accessit Nervorum Descriptio et Usus*. London: Martyn & Allestry; 1664:95.
5. Petit JL. *Chirurg Mem de l'Acad Roy des Sciences*. Paris: Royal Academy of Science; 1765.
6. Tindall GT, Goree JA, Lee JF, Odom GL. Effect of common carotid ligation on size of internal carotid aneurysms and distal intracarotid and retinal artery pressures. *J Neurosurg*. 1966;25:503–511. doi: 10.3171/jns.1966.25.5.0503.
7. Abercrombie J. *Pathological and Practical Researches on Diseases of the Brain and the Spinal Cord*, 3rd ed. Philadelphia, PA: Carey, Lea & Blanchard; 1836:208–209.
8. Carswell R. *Pathological Anatomy: Illustrations of the Elementary Forms of Disease*. London: Longman, Orme, Brown, Green & Longman; 1838.
9. Gull WW. Thickening and dilatation of the aorta with occlusion of the innominate and left carotid, atrophic softening of the brain. *Guys Hosp Rep*. 1855;1:12.
10. Savory WS. Case of a young woman in whom the main arteries of both upper extremities and of the left side of the neck were throughout completely obliterated. *Med Chir Trans*. 1856;39:205–219.
11. Kussmaul A. Zwei Fälle von spontaner allmählicher Verschlussung grosser Halsarterienstämme. *Dtsch Arch Klin Med*. 1872;24:461–465, 473–474.
12. Penzoldt F. Ueber Thrombose (autochthone oder embolische) der Carotis. *Dtsch Arch Klin Med*. 1881;28:80–93.
13. Fisher M. Occlusion of the internal carotid artery. *AMA Arch Neurol Psychiatry*. 1951;65:346–377.
14. Fisher M. Occlusion of the carotid arteries: further experiences. *AMA Arch Neurol Psychiatry*. 1954;72:187–204.
15. Kerber CW, Cromwell LD, Loehden OL. Catheter dilatation of proximal carotid stenosis during distal bifurcation endarterectomy. *AJNR Am J Neuroradiol*. 1980;1:348–349.

KEY WORDS: atherosclerosis ■ carotid disease ■ stroke history ■ stroke prevention ■ stroke